

A Clinical Study on Intra-Operative and Delayed Complication in Surgical Management following Peri-trochanteric Fracture of Femur Using Proximal Femoral Nail

Akshay TM, Naganagoudar IH

Department of Orthopaedics, MVJ College and Hospital, Bangalore, Karnataka

ABSTRACT

Background: Peritrochanteric fractures are devastating injuries that most commonly affect the elderly population. Peritrochanteric fracture is a leading cause of hospital admissions in elderly people. Conservative methods of treatment results in malunion with shortening and limitation of hip movement as well as complications of prolonged immobilization like bed sores, deep vein thrombosis and respiratory infections.

Aim: This study is done to analyze the surgical management of Peritrochanteric fractures using Proximal Femoral Nail.

Methods: This was a prospective study of 30 cases of fresh inter -trochantric and subtrochanteric fractures admitted at Navodaya Medical College Hospital and Research Centre, Raichur, between July 2011 to October 2012.

Results: Our study consisted of 33 cases of peritrochanteric fractures of femur treated surgically by Proximal Femoral Nail (PFN) between July 2011 to October 2012. 30 patients were available for follow-up. The number of male patients in our series were 21(70%) and female patients were 9(30%) in number. Intra-operative complications were seen in 7 cases and delayed complications were seen in 9 cases. Inter - trochanteric and subtrochanteric fracture were 15 in each group. Complications were more common with inter-trochanteric fracture, but it was not statistically significant. There was no difference between direct and indirect mode of injury. Result following operation was classified into excellent, good, fair and poor. When result was compared with complication p value was found to be 0.02, which is statistically significant.

Conclusion: From this study, we consider that proximal femoral nail is an excellent implant for the treatment of Peritrochanteric fractures.

Key Words: Proximal femoral nail; Peritrochanteric; Subtrochanteric; Inter-trochanteric

Introduction

Peritrochanteric fractures of femur are devastating injuries that most commonly affect the elderly. In the elder age group most of the fractures are due to osteoporotic bone, resulting from a trivial fall^[1]. These fractures have a tremendous impact on both the health care system and society in general. Peritrochanteric fractures comprise

fractures of intertrochanteric and subtrochanteric region. In 1996, the Arbeitsgemeinschaft für Osteosynthesefragen (AO/ASIF) developed the Proximal Femoral Nail (PFN) as an intramedullary device for the treatment of unstable intra- and sub-trochanteric femoral fractures.

Intertrochanteric fractures can be managed by conservative methods, but malunion and

Address for Correspondence

Dr. Akshay TM, Assistant Professor, Department of Orthopaedics, MVJ College and Hospital, Bangalore, Karnataka
E-mail: akshaytm@gmail.com

complications of prolonged immobilization is the end result. Thus, surgery by internal fixation is the ideal choice. Dynamic hip screw (DHS) is the gold standard treatment for inter-trochanteric fractures^[2]. Subtrochanteric fractures are femoral fractures where the fractures occur below the lesser trochanter to 5 cm distally in the shaft of femur^[1]. The present choice of treatment of subtrochanteric fractures is open reduction and internal fixation. Subtrochanteric fractures are complicated by malunion and delayed or nonunion. The aim of the present study was to analyze the results of peri-trochanteric fractures with respect to intra-operative details, post-operative results and functional outcome.

Objectives:

1. To study the types of Peritrochanteric Fracture
2. To study the intra-operative and delayed complication in Surgical Management Of Peritrochanteric Fracture (PTF) of Femur Using Proximal Femoral Nail (PFN)

Materials and Methods

This was a prospective study conducted in Navodaya Medical Hospital and Research Centre Raichur, from July 2011 to October 2012. During this period 33 cases of adult patients with peritrochanteric fractures of femur were selected according to the inclusion criteria. The fractures were subdivided into inter-trochanteric fractures and sub-trochanteric fractures. Intertrochanteric fractures were classified according to Boyd & Griffith's classification. Subtrochanteric fractures were classified according to Seinsheimers classification. 3 were lost to follow up. 30 cases were followed up at regular intervals.

Inclusion criteria:

1. Unstable Inter-trochanteric fractures {Reverse oblique fractures and Inter Trochanteric fractures with loss of posteromedial cortex}
2. Sub-trochanteric fractures in adults.

Exclusion criteria:

1. Intertrochanteric fractures involving piriformis fossa.
2. Stable intertrochanteric fractures.
3. Open hip fractures.
4. Pathological fractures.

5. Below 18yrs of age.
6. Not willing to participate in study.

Preoperative planning:

1. Determination of nail diameter by measuring the diameter of femur at the level of isthmus on AP view.
2. Length of hip screws and distal locking bolts on the AP view
3. Neck shaft angle

Proximal femoral nail-implant details:

The implant consists of a proximal femoral nail, self tapping 6.5mm derotation screw, and 8mm hip/lag screw and 4.9 mm distal locking bolts. End cap was optional. The nail is made up of 316L stainless steel or titanium alloy. The nail is available in following sizes

1. Length-standard PFN-250mm, Long PFN-340mm, 380mm, and 420mm
2. Diameter-9, 10, 11mm.
3. Neck shaft angle-125°, 130°, 135°.

From above to below, the nail has a proximal diameter of 14mm which increases the stability of the implant and hold. There is a 6 degree valgus angle which prevents varus collapse of the fracture and allows for insertion through the tip of the greater trochanter. Proximally it has two holes forming a neck shaft angle. The distal is for insertion of the 8mm hip/lag screw which acts as a sliding screw. The proximal hole is for insertion of the 6.5mm derotation screw which helps to prevent rotation and increases the stability. The distal diameter is tapered to 9 to 11mm, which also has grooves to prevent stress concentration at the end of the nail and avoids periprosthetic fracture at the tip of the nail.

In our study we used a standard PFN of 250mm and long PFN of 320mm, 340mm with distal diameter of 9, 10, & 11 mm, with the proximal diameter of 14mm. The proximal derotation screw of 6.5mm and hip screw of 8mm. Distal locking was done with 4.9mm bolts. The nail is universal with 6 degrees mediolateral angulation and with a neck shaft angle of 135 degrees.

Operative Technique:

Percutaneous fixation of fracture: In intertrochanteric fractures, fracture was fixed

percutaneously using k wires anteriorly and posteriorly to avoid displacement of fragments while insertion of nail. Insubtrochanteric fractures, a Steinmann fracture was inserted in the proximal fragment anteriorly to control the proximal fragment by using the pin as a joystick to correct abduction forces and aid in reduction.

Insertion of the nail: An appropriate size nail as determined preoperatively was assembled to the insertion handle and inserted manually over the guide wire using gentle twisting movements of the handle till the 8mm hip screw hole coincides with the inferior aspect of the neck in the image intensifier.

Insertion of guide wires for the neck screws: A 1.8mm guide wire was inserted through the sleeves after a stab incision for the 8 mm neck screw. Similarly, another guide wire was inserted through the proximal hole for insertion of the 6.5mm derotation screw.

Insertion of hip and derotation screws: The derotation screw is inserted first to prevent the possible rotation of the proximal fragment when inserting the hip screw. Using 8mm cannulated drill, the neck was opened over the guide wire up to the desired length. Tapping was done over the guide wire. The appropriate 8mm hip screw is inserted with the hexagonal cannulated screw driver. Final position was confirmed under image intensifier.

Distal locking: Distal locking is usually performed with 4.9mm locking bolts Locking bolt was inserted through the sleeve and confirmed under image intensifier.

Follow up: All patients were followed up at 4 weeks, 10 weeks and every 6 weeks thereafter till fracture union is noted. Then at 6 months, 9 months and 1year. X ray of the involved hip with femur was done to assess fracture union and implant bone interaction

Results

30 patients were available for follow-up. In our series maximum age was 75years & minimum aged patient was of 25 years, with an average age of 50yrs. The numbers of male patients in our series were 21(70%) and female patients were 9(30%) in number (Table 1). Inter - trochanteric and subtrochanteric fracture were 15 in each group. In inter-trochanteric

fractures 40% belonged to type IV, 33% belonged to type II and 27% to type III (Of Boyd and Griffin classification) (Table2). In subtrochanteric fractures 53% belonged to type IIA, 20% belonged to type IIIA and 13% belonged to IIB (of Seinsheimer's classification) (Table3).

Complications encountered in our study are divided into intra-operative and post-operative complications. Intra -operative complications were (Table 4)

1. Jamming of nail in the proximal fragment while insertion was noted in one case, requiring progressive reaming of the proximal fragment and use of lesser diameter nail.
2. Failure in insertion of derotation screw in 4 cases.
3. In 1 case we failed to lock distally due to mismatch of the zig and nail
4. In 1 case fixation of the fracture in varus angulation took place.

Delayed complication (Table 5) was seen in 9 cases. 3 cases (33.4%) of delayed union were present, these cases of delayed union required dynamization which were followed up till bony union. A case of excessive collapse was noted in intertrochanteric fracture type III with prominence of the screws laterally. 1 case (11.1%) with shortening of 1 cm was seen due to the excessive comminution noted in the fracture. One case (11.1%) of non union/ Z effect was noted, it was attributed to the open reduction procedure and no bone grafting was done. Exchange nailing with interlocking nail and bone grafting was done. Varus angulation was seen 1 case(11.1%). Stiffness of hip was noted in 2 cases (22.2%). Stiffness of knee was noted in 1 case (11.1%) which required vigorous physiotherapy, with full recovery of the range of movements.

Distribution of study subjects with complications and without complications is shown in table 6. Complications were more common in females compared to males. Complications were more common in inter-trochanteric fracture, but were not statistically significant. There was no difference between direct and indirect mode of injury. Results were classified into excellent, good, fair and poor. When result was compared with and without complication, p value was found to be 0.02 which is statistically significant.

Table 1. Age and gender distribution of the cases

Age group	Number of cases	
	Males (%)	Females (%)
21-40 yrs	7 (33.3)	3 (33.3)
41-60 yrs	12 (57.1)	6 (66.7)
61-80 yrs	2 (9.6)	0
Total	21 (100)	9 (100)

Table 2. Boyd and Griffin classification of fracture

Type of fracture	No. of cases	Percentage
Type II	5	33
Type III	4	27
Type IV	6	40
Total	15	100

Table 3. Seinsheimer's classification of fracture

Type of fracture	No of cases	Percentage
Type IIA	8	53
Type IIB	2	13
Type IIIA	3	20
Type IV	1	07
Type V	1	07
Total	15	100

Table 4: Intra-operative Complications

Intraoperative Complications	Number of Cases	Percentage
Jamming of nail	1	14.3
Failure in derotation screw	4	57.1
Failure in distal locking	1	14.3
Varus angulation	1	14.3
Fracture of lateral cortex	0	0
Femoral fracture	0	0
Total	7	100

Table 5. Delayed complications

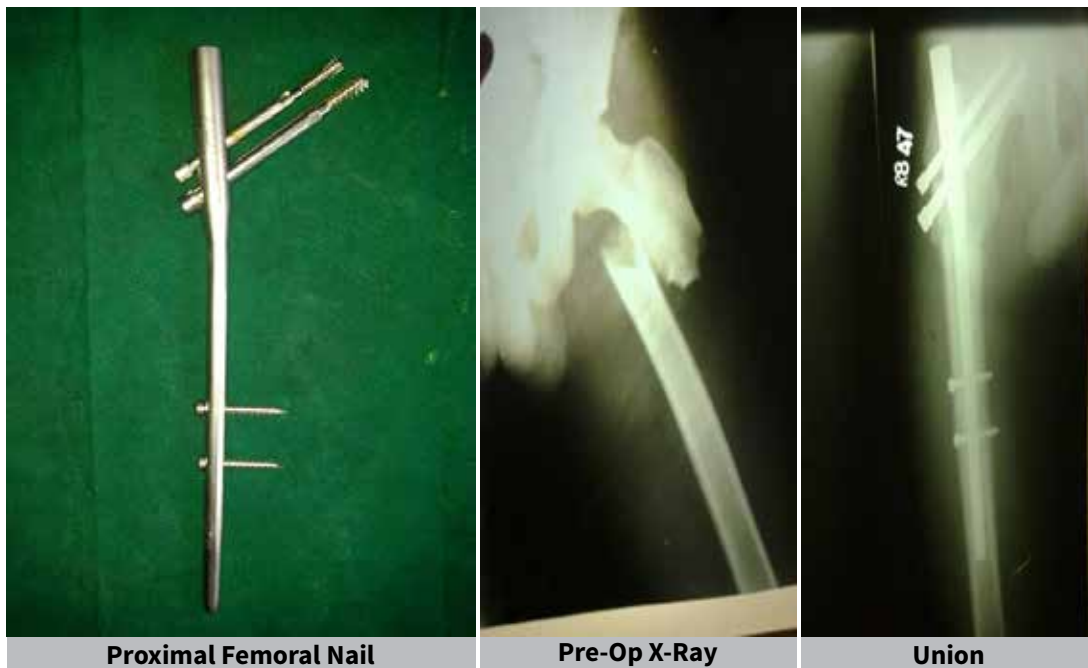
Delayed complications	Number of Cases	Percentage
Hip joint stiffness	2	22.2
Knee joint stiffness	1	11.1
Delayed union	3	33.4
Shortening	1	11.1
Implant failure	0	0
Varus angulation	1	11.1
Z Effect/non union	1	11.1
Total	9	100

Table 6: Cases with and without complications under various categories

	Number (%) of cases with complications	Number (%) of cases without complications	p-value
Gender			
Male	5 (16.7)	16 (53.3)	0.91
female	5 (16.7)	4 (13.3)	
Total	10 (33.4)	20 (66.6)	
Inter-trochanteric fracture			
II	1(6.7)	4 (26.6)	0.146
III	3 (20)	1 (6.7)	
IV	3 (20)	3 (20)	
Total	7 (46.7)	8 (53.3)	
Subtrochanteric fracture			
IIA	2 (13.3)	6 (40)	0.634
IIB	0	3 (20)	
IIIA	1 (6.6)	1 (6.7)	
IV	0	1 (6.7)	
V	0	1 (6.7)	
Total	3 (19.9)	12 (80.1)	

Age group:			
21-40	3 (10)	7 (23.4)	1.0
41-60	6 (20)	12 (40)	
61-80	1 (3.3)	1 (3.3)	
Total	10 (33.3)	20 (66.7)	
Side of injury			
Right	7 (23.4)	10 (33.3)	0.29
Left	3 (10)	10 (33.3)	
Total	10 (33.4)	20 (66.6)	
Mode of injury			
Direct	5 (16.7)	4 (13.3)	0.91
Indirect	5 (16.7)	16 (53.3)	
Total	10 (33.4)	20 (66.6)	
Prognosis			
Excellent	2 (6.7)	5 (16.7)	0.02*
Good	4 (13.3)	0	
Fair	3 (10)	15 (50)	
Poor	1 (3.3)	0	
Total	10 (33.3)	20 (66.7)	

* Statistically significant



Discussion

In a study done by Laskin, Gruber and Zimmerman found that early operative treatment of peri-trochanteric fractures reduces both mortality and morbidity, giving best chance of early independency and reducing the risks of prolonged bed rest^[3]. In the management of peri-trochanteric fractures of femur, it is atmost importance to re-establish bone to bone contact of the posteromedial cortex. Study done by Leung et al revealed that Intramedullary

fixation allows the surgeon to minimize soft tissue dissection thereby reducing surgical trauma, blood loss, infection, and wound complications^[4]. The Proximal femoral nail (PFN) AO-ASIF device introduced in early 1997 was designed to reduce the risk of implant related complications. Boldin C in their study concluded in their study that proximal femoral nail is a good minimal invasive implant of unstable proximal femoral fractures, if closed reduction is possible^[5].

In a study done by Ramakrishnan, reported their experience with long proximal femoral nail for complex subtrochanteric femur fractures and concluded it as a reliable implant with mandatory posteromedial reconstruction to avoid mechanical failure and non union^[6].

In a study done by Menezes, noted low rates of femoral shaft fractures and failure of fixation with proximal femoral nail and recommended it for treatment of unstable inter-trochanteric and subtrochanteric fractures^[7].

Intramedullary nails may have advantages over extramedullary fixation using fixed angle plates for more distal reverse and transverse transtrochanteric (AO type A3) fractures, and subtrochanteric fractures, although there is as yet insufficient evidence to confirm significant superiority over extramedullary devices. Intramedullary (IM) nail stabilization is the accepted gold standard for treating femoral shaft fractures, with reported union rates as high as 99%.

In our study the average age of the patient at fracture was 50 years, this was lower compared to that quoted by authors in literature Parker of 71 years^[8], Boldin of 73 years^[5], Pavelka of 67 years^[9]. In our study we had male preponderance of 21 patients (70%) out of 30 patients. Higher female preponderance was reported by Boldin of 70%^[5] and Pavelka of 60%^[9].

In our study we had 15% of failure rates due to poor anatomic reduction. We had no case of intra-operative fracture displacement after nail insertion, Simmermacher in a clinical multicentre study reported technical failures of the PFN after poor reduction, malrotation or wrong choice of screws in 5% of cases^[10].

In our study failure of fixation occurred in 10% (2 cases), which included 1 case of varus angulation and a non-union. We had no cases of ipsilateral femoral shaft fracture in our study. Menezes 2005 in a clinical study of 155 consecutive patients treated with proximal femoral nail, reported failure of fixation in 2%, femoral shaft fractures in 0.7%, fixation failures included one cut out, one delayed fracture healing and one lateral displacement of the anti rotation screw^[7].

In our study there was a case with Z effect, with good selection of screw lengths and shorter derotation screw. Boldin in his study of 55 patients of proximal

femoral fractures with PFN noted 3 cases with Z effect and 2 patients with Reverse Z effect. 2 patients had screw cut-out without any relation to fracture pattern^[5].

We had bony union in 93% cases in an average of 4 months, with no iatrogenic femoral fracture, Pavelka in his study of 147 patients with proximal femoral fractures treated with PFN noted fracture healing in 95% patients in 6 months, with intra-operative complications like incomplete reduction in 4 cases^[9].

Conclusion

Peritrochanteric fracture of the femur is common in the elderly due to osteoporosis. Proximal femoral nail, inspite of few unfavourable results and complications, is a satisfactory method of treatment in peritrochanteric fractures, with comminution and instability. It requires closed monitoring during pre, intra and postoperative period to avoid complications, which can be easily managed.

References

1. Buchholz RW, Heckman JD, Brown CM. *Rockwood and Green's Fractures in adults*. 6th ed. Vol 2. Wolters Kluwer; 2009. p. 1827- 44.
2. Kulkarni GS, Limaye R, Kulkarni M. *Intertrochanteric Fractures*. *Indian J Orthop* 2006; 40: 16-23.
3. Laskin R, Gruber MA, Zimmerman AJ. *Intertrochanteric Fracture Of Elderly: A Retrospective Analysis of 236 cases*. *Clin Ortho Rel Res* 1979 Jun;141:188-95.
4. Leung KS, So WS, Shen WY, Hui PW. *Gamma nails and dynamic hip screws for peritrochanteric fractures*. *J Bone Joint Surg (Br)* 1992; 74: 345-51.
5. Boldin C, Seibert FJ, Fankhauser F, Peicha G, Grechenig W and Szyszkowitz R. *The proximal femoral nail (PFN): a minimal invasive treatment of unstable proximal femoral fractures*. *Acta Orthop Scand* 2003; 74 (1): 53-8.
6. Mereddy P, Kamath S, Ramakrishnan M, Malik H, Donnachie N. *The AO/ASIF proximal femoral nail antirotation (PFNA): A new design for the treatment of unstable proximal femoral fractures*. *Injury* 2009; 40: 428-32.
7. Menezes DF, Gamulin A, Noesberger B. *Is the Proximal femoral nail a suitable implant for treatment of all trochanteric Fractures?* *Clin Ortho Rel Res* 2005 Oct; 439: 221-7.
8. Parker MJ, Pryor GA. *Gamma versus DHS nailing for extracapsular femoral fractures: meta-analysis of ten randomized trials*. *Int Orthop* 1996; 20:163-8.
9. Pavelka T, Kortus J, Linhart M. *"Osteosynthesis of proximal femoral fractures using short proximal femoral nails"*. *Acta Chir Orthop Traumatol Cech* 2003;70(1): 31-8.
10. Simmermacher RK, Bosch AM, Werken CV. *The AO/ASIF-proximal femoral nail (PFN): a new device for the Treatment of unstable proximal femoral fractures*. *Injury* 1999; 30: 327-32.

Conflict of interest: **Nil**

Source of funding: **Nil**